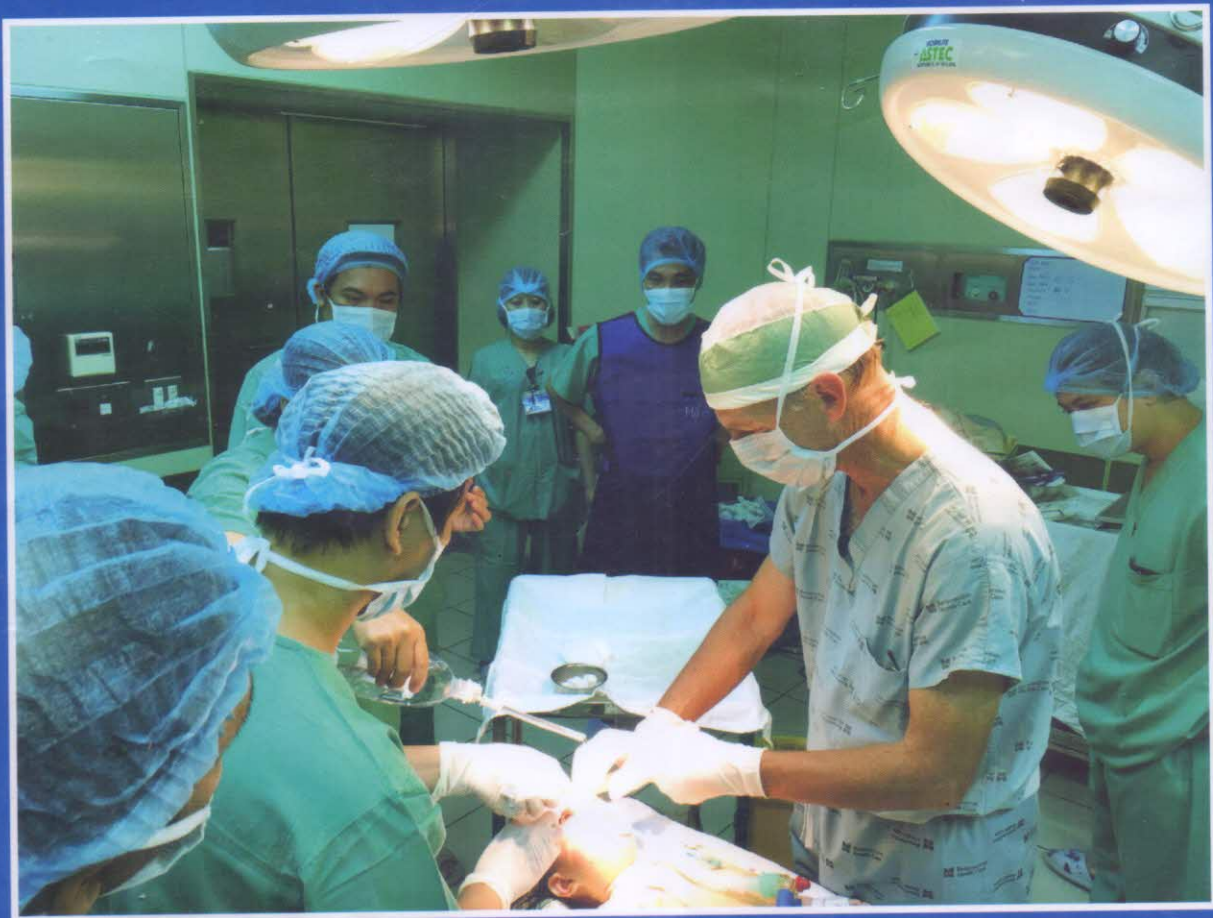




HUE CENTRAL HOSPITAL

ISSN 1859 - 3895

# JOURNAL OF CLINICAL MEDICINE



*Forum of medicine*

No.51 - 2018

## MỤC LỤC

39	8.	A Case Report: Melanotic Neuroectodermal Tumor Of Infancy: Diagnose And Treatment - <i>Tran Kiem Hao, Nguyen Thi Hong Loi, Phan Canh Duy, Nguyen Thi Kim Hoa, Tran Xuan Phu, Nguyen Van Khanh, Hoang Ngoc Thach.</i>	45
51	10.	Long-term follow-up results of single port laparoscopic right hemicolectomy - <i>Ho Huu Thien, Phan Hai Thanh, pham Trung Vy, Nguyen Thanh Xuan, Van Tien Nhan, Tran Nghiem Trung, Pham Xuan Dong, Mai Trung Hieu, Pham Nhu Hiep.</i>	56
63	12.	Vinorelbine As Second-Line Treatment Of Nsclc After The Failure Of Platinum-Taxane combination At the hue university hospital - <i>Ho Xuan Dung, Le Vi, Nguyen Tuan Phat, Tran Doan Quoc Long, Lê Gia Han, Nguyen Thi Thuy.</i>	68
3	1.	The Result Of Ccg 1961 Protocol Treatment With High Risk Acute Lymphoblastic Leukemia In Children - <i>Nguyen Thi Mai Huong, Bui Van Vien, Tran Thu Ha, Bui Ngoc Lan, Phung Tuyet Lan, Nguyen Thi Huong.</i>	3
8	3.	Characteristics of immunologic markers in pediatric acute lymphoblastic leukemia with genetic mutation at national institute of hematology and blood transfusion from 2016 to 2018 - <i>Hoang Thi Hong, Mai Lan, Nguyen Quang Tung, Nguyen Trieu Van, Bach Quoc Khanh.</i>	8
12	4.	Analysis of Relapse childhood acute lymphoblastic leukemia at hue central hospital in vietnam - <i>Nguyen Thi Kim Hoa Tran Kiem Hao, Chau Van Ha, Kazuyo Watanabe.</i>	12
19	5.	A study of pathological characteristics of Pediatric non-hodgkin lymphoma based on 2008 version of The world health organization classification Of lymphoid neoplasms at Children's Hospital 1 - <i>Phan Dang Anh Thu, Tran Thanh Tung, Nguyen Minh Tuan, Cao Tran Thu Cuc.</i>	19
25	6.	Assessment of surgical treatment of wilm's tumors in children according to sip 2001 - <i>Dang Huu Chien, Truong Dinh Kha.</i>	25
32	7.	Evaluation of the results of Laparoscopic Debulking Surgery in the Management of Advanced Ovarian Cancer After Neoadjuvant Chemotherapy at Hue Central Hospital - <i>Chau Khac Tu, Le Sy Phuong, Le Minh Toan, Bach Cam An, Lê Thị Ý Nhan.</i>	32

## VINOURELBINE AS SECOND-LINE TREATMENT OF NSCLC AFTER THE FAILURE OF PLATINUM-TAXANE COMBINATION AT THE HUE UNIVERSITY HOSPITAL

Ho Xuan Dung<sup>1</sup>, Le Vi<sup>1</sup>, Nguyen Tuan Phat<sup>1</sup>,  
Tran Doan Quoc Long<sup>1,2</sup>, Le Gia Han<sup>1</sup> Nguyen Thi Thuy<sup>1</sup>

### ABSTRACT

Lung cancer is the most prevalent malignancy and the leading death caused by cancer worldwide. It is also the most common cancer in Vietnam. With the high prevalence and high mortality rate, lung cancer is the real burden of healthcare today. NSCLC accounts for about 85-90% of lung cancer. Lung cancer is mostly diagnosed at a late stage that the goal of the treatment is palliative. The advent of new targeted therapies for NSCLC is making a huge change in the practice of lung cancer treatment. But due to lacking resources, chemotherapy is still playing an important role in Vietnam. After the first-line chemotherapy, patients degrades a lot and it raises the question of choosing an appropriate drug for the continuous treatment. Vinorelbine was found to be effective in NSCLC treatment and it was introduced in Vietnam in 2006. Some studies showed its efficacy in treating NSCLC at a late stage of the first line in Vietnam but lacking information on vinorelbine application for second-line treatment.

**Methods:** A retrospective cohort study of 32 patients with NSCLC staged IIIB-IV treated by vinorelbine as second-line after the failure of Paclitaxel and carboplatin combination for the first-line at the Hue University hospital from 2013-2017. Vinorelbine was administered on day 1, day 8 and day 21.

Statistical analysis was performed in R program.

**Results:** Our study composed of a higher rate of squamous cell carcinoma (43.75%) versus adenocarcinoma (28.12%). 78.13% were at stage IV. The most common metastatic sites were lung, pleura, and bone. The response rate was 28.13%. No cases of complete response were observed. Symptoms were improved in 19 patients (59.34%). The median of OS was 41 weeks. Anemia, neutropenia, and nausea were the most frequently observed in only one case of grade IV anemia.

**Conclusion:** Vinorelbine was found to be effective with high tolerability as a second-line treatment for NSCLC at stage IIIB-IV.

**Keywords:** NSCLC, lung cancer, vinorelbine, second-line.

### I. INTRODUCTION

Lung cancer is the most prevalent malignancy with 1.8 million newly diagnosed cases in 2012 and the leading death caused by cancer with about

1.59 million died of this cancer worldwide. It is also the most common cancer in Vietnam with high mortality [1], [2], [3], [4] thus enabling behavior to vary adaptively from moment to moment.

1. Hue University of Medicine and Pharmacy  
2. Medical center of Phu Vang district,  
Thua Thien Hue province

- Received: 29/7/2018; - Revised: 16/8/2018;  
- Accepted: 27/8/2018  
- Corresponding author: Ho Xuan Dung  
- Email: [xuandung59@gmail.com](mailto:xuandung59@gmail.com); Tel: 0982558945

## Hue Central Hospital

Dominating contemporary research on this topic is the viewpoint that self-control relies upon a limited resource, such that engaging in acts of restraint depletes this inner capacity and undermines subsequent attempts at control (i.e., ego depletion). With the high prevalence and high mortality rate, lung cancer is the real burden of healthcare today for every country.

Lung cancer is composed of small cell lung cancer and non-small cell lung cancer (NSCLC). In which, NSCLC accounts for about 85-90% of lung cancer [4]. Lung cancer is mostly diagnosed at a late stage that the goal of the treatment is palliative. The advent of new targeted therapies for NSCLC is making a huge change in the practice of lung cancer treatment [1], [4]. But due to lacking resources, chemotherapy is still playing an important role in Vietnam, especially in central Vietnam where local people are still poor. A doublet of platinum-based regimen is usually indicated for patients with NSCLC staged IIIB-IV whose general status OMS was 0-2. Taxane and carboplatin regimen is widely used for the first line of the treatment with comparable efficacy to other chemotherapy combinations and acceptable toxicities. After the failure of this first-line treatment, patients normally degrades a lot and it raises the question of how to choose an appropriate chemotherapy. For second-line chemotherapy, monotherapy is preferred and among many, third generation drugs, docetaxel was found to have higher efficacy in comparison to others chemotherapy drugs but the toxicities are more serious. [4], [5], [6].

Vinorelbine has been introduced in Vietnam since 2006. Some studies examined the combination of vinorelbine + platinum in treating NSCLC stage IIIB-IV for the first-line. These studies showed that vinorelbine in combination with platinum had the good outcome and fewer toxicities [7], [8]. But lacking studies of vinorelbine monotherapy after

the failure of platinum doublet especially taxane and carboplatin. The application of vinorelbine in Hue in recent years without known report to the authors. So, we conducted the study "vinorelbine as second-line treatment of NSCLC after the failure of the platinum-taxane combination at the Hue University hospital" with aims:

- To describe the characteristics of NSCLC at late stage treated at the Hue University hospital with vinorelbine as the second-line treatment after the failure of carboplatin and taxane regimen.
- To reveal the efficacy of vinorelbine as a second-line monotherapy.
- To depict the toxicities of vinorelbine.

## II. PATIENTS AND METHODS

A retrospective cohort study of 32 patients with NSCLC staged IIIB-IV treated with vinorelbine after the failure of the Paclitaxel and carboplatin regimen for the first line at the Hue University hospital from 2013-2017. Vinorelbine was administered on day 1-8 every 21 days, at least 3 cycles of the treatment. Vinorelbine day 1 at 25-30 mg/m<sup>2</sup> IV, Vinorelbine day 8 at 60-80 mg/m<sup>2</sup> day 8. We excluded those cases that lack needed information.

We measured overall survival from the time of treating vinorelbine till death or last follow up if patients are still alive. The response of the chemotherapy was evaluated by RECIST criteria. Statistical analysis was performed by R program.

## III. RESULTS

### 3.1 Description of the subjects

In our study group, the mean age was 58 years old with a range from 45-79. The male/female ratio was 1.67: 1. Pathologically, the squamous cell carcinoma was much higher than adenocarcinoma (43.75% vs 28.12%). Patients were majorly at stage IV with the percentage of 78.13% (Table 1).

Pleura, lungs and bone were among the most common sites of metastasis (Table 2, 3)

Table 1. Some common characteristics of the study group

Characteristics		n	%
Gender	male	20	62.5%
	female	12	37.5%
Affected lung	left	17	53.13
	right	15	46.87
Pathology	squamous	14	43.75
	adenocarcinoma	9	28.12
	mixte	1	3.13
	large cell	2	6.25
	unknown type	6	18.75
Stage of cancer	stage IIIB	7	21.87
	stage IV	25	78.13

In the study group, male patients were more prevalent than women, squamous cell carcinoma was found dominantly and patients were almost metastatic with stage IV of 78.13%.

Table 2. Metastatic sites at the time of diagnosis

Site of metastasis	n	%
liver	2	7.41
pleura	14	51.85
pericardium	2	7.41
lungs	11	40.74
bone	10	37.04
kidney	1	3.70
brain	1	3.70

Table 3. Metastatic sites before vinorelbine

Metastatic sites before vinorelbine	n	%
Liver	4	12.5
Pleura	15	46.88
Brain	3	9.38
Lungs	16	50.00
Adrenal glands	1	3.13
Bone	13	40.63

The most common metastatic sites at the time of diagnosis and before treating vinorelbine were

lungs, pleura, bone, brain in order of high to low prevalence.

### 3.2 The outcome of the treatment

After 3 cycles of chemotherapy, 18 cases were found to have progression of the disease, 9 cases were partially responded and 5 were stable. The response rate was 28.13%. There were no cases of complete response.

About the clinical response, symptoms were observed to be improved after 3 cycles of vinorelbine in 19 patients (59.34%).

The survival analysis showed that the median of OS was about 41 weeks (about 10 months) and the survival rate was higher in patients with stage IIIB (p=0.45). (Figure 1).

Table 4. Response rate of vinorelbine

Response	n	%
Complete response	0	0
Partial response	9	28.12
Stable disease	5	15.63
Progression	18	56.25

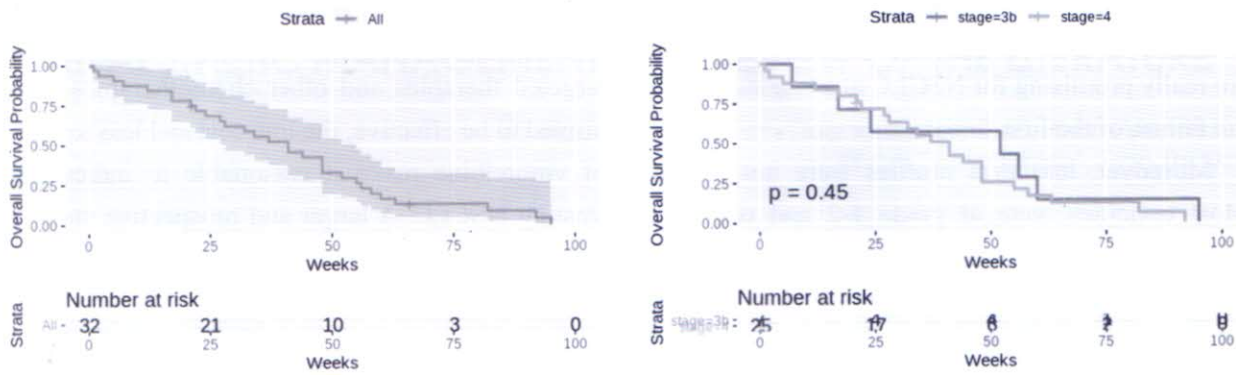


Figure 1. Overall survival analysis

**3.3. Toxicities of vinorelbine**

Most toxicities were grade 1-2. Anemia, neutropenia, and nausea were the most frequently observed toxicities in patients treated with vinorelbine. The rate of patients got anemia, neutropenia and nausea at all grades were 31.25%, 21.88% and 25% respectively. One patient had anemia grade 4 (Table 4).

Table 4. Toxicities of Vinorelbine

Toxicity	All grades	Grade 3-4
<b>Hematological</b>		
Thrombocytopenia	1 (3.13%)	0
Neutropenia	7 (21.88%)	0
Anemia	10 (31.25%)	1 (3.13%)
<b>Non-hematological</b>		
Nausea	8 (25%)	0
Vomitting	2 (6.25%)	0
Diarrhea	3 (9.38%)	0
Sensorial neuropathy	3 (9.38%)	0
Mucositis	1(3.13%)	0
Extravasation	2 (6.25%)	0

**IV. DISCUSSION**

From our cohort of 32 patients with NSCLC stage IIIB-IV. The mean age was 58 years old. The youngest patient was 45 and the oldest was 79. The male/female ratio was 1.67: 1. These are rather similar to some studied cohorts in the north of Vietnam [8], [9]. The rate of adenocarcinoma in our study was lower to other authors [8], [9] [10]. This may due to the high rate of unknown types in our study. More elective studies with the exclusion of cytology confirmation may explain this difference more clearly.

The most common metastatic sites were pleura, lungs, and bone. This is well known in the literature of lung cancer.

In term of the efficacy of Vinorelbine, the response rate was 28.13% which is higher than the rate from the western countries [5] but rather similar to the author Le Chinh Dai at the K hospital [9]. This rate of response rate was lower than the author Nguyen Huu Khiem in which, the response rate was 33.5% and 35.1% for stage IIIB and IV. These differences may come from the difference in pathology, the previous treatment.

A good clinical response was observed at 59.34%. And the median OS was 41 weeks. These findings are really promising for NSCLC at a late stage after the failure of the first-line therapy.

Moreover, toxicities profiles were not severe. Most toxicities were at grade 1-2 and only one grade 4 of anemia was observed and easily managed by transfusion. Many international and local studies of vinorelbine also found the same remark that vinorelbine is tolerable to NSCLC patients and the grade 3-4 toxicities are minimal. [8], [9], [11] excluding non-melanoma skin cancer. Non-small cell lung cancer (NSCLC)

Our findings showed that vinorelbine could be

another option for NSCLC which progresses after the first line of platinum-taxane. Though many targeted therapies and other chemotherapies were proved to be effective, the low cost and less toxicity of vinorelbine make it reasonable to indicate in treating NSCLC. A larger and prospective study is needed to confirm our findings.

## V. CONCLUSION

Vinorelbine was found to be effective with high tolerability as a second-line treatment for NSCLC at stage IIIB-IV. The result needs a well structured larger prospective study to confirm for more conclusive findings.

## REFERENCES

1. Postmus P.E., Kerr K.M., Oudkerk M. et al. (2017). Early and locally advanced non-small-cell lung cancer (NSCLC): ESMO Clinical Practice Guidelines for diagnosis, treatment and follow-up†. *Ann Oncol*, 28(suppl\_4), iv1-iv21.
2. Bray F., Ren J.-S., Masuyer E. et al. (2013). Global estimates of cancer prevalence for 27 sites in the adult population in 2008. *Int J Cancer*, 132(5), 1133–1145.
3. Torre L.A., Bray F., Siegel R.L. và cộng sự. (2015). Global Cancer Statistics, 2012. *CA a cancer J Clin*, 65(2), 87–108.
4. Novello S., Barlesi F., Califano R. et al. (2016). Metastatic non-small-cell lung cancer: ESMO Clinical Practice Guidelines for diagnosis, treatment and follow-up†. *Ann Oncol*, 27(suppl\_5), v1–v27.
5. Gridelli C., Ardizzoni A., Ciardiello F. et al. (2008). Second-Line Treatment of Advanced Non-small Cell Lung Cancer. *J Thorac Oncol*, 3(4), 430–440.
6. Fossella F. V, Lynch T., và Shepherd F.A. (2002). Second line chemotherapy for NSCLC: establishing a gold standard. *Lung Cancer*, 38 Suppl 4(1), 5–12.
7. Hòa N.T.T., Tú Đ.A., Toàn V.Q. và cộng sự. (2010). Đánh giá hiệu quả điều trị bước đầu của phác đồ hóa chất vinorelbine- cisplatin đối với ung thư phổi không tế bào nhỏ giai đoạn muộn. *Thông tin y dược*, (9), 2008–2011.
8. Vũ Thị Loan, Cẩn Tuyết Nga L.T.L. (2017), *Khảo sát tình hình sử dụng vinorelbine trong điều trị ung thư phổi không tế bào nhỏ tại Trung tâm Y học hạt nhân và ung bướu - Bệnh viện Bạch Mai*, .
9. Đại L.C. (2014). Đánh giá hiệu quả hóa trị phác đồ vinorelbine- cisplatin bệnh ung thư phổi không tế bào nhỏ giai đoạn IIIB-IV. *Y học et al. Việt Nam*, (2), 4–8.
10. Vũ Hữu Khiêm (2017), *Đánh giá kết quả điều trị ung thư phổi không tế bào nhỏ bằng phác đồ Hóa-xạ trị với kỹ thuật PET/CT mô phỏng*, Đại học Y Hà Nội.
11. Faller B.A. và Pandit T.N. (2011). Safety and Efficacy of Vinorelbine in the Treatment of Non-Small Cell Lung Cancer. *Clin Med Insights Oncol*, 5, CMO.S5074.